MAIN MESSAGE

- **Oral foci of infection may lead to severe systemic infections. Where clinically appropriate, these should be eliminated before liver transplantation.**
- **Conventional coagulation tests, including the International Normalized Ratio (INR) and platelet count, have limited predictive value for procedure-related bleeding in patients with liver disease.**
- **In patients with advanced or decompensated liver disease, dental treatment should be individualized, and management in a hospital setting should be considered.**

AUTHORS

Ole Kristian Lobekk, Dentist and Specialty Registrar in Maxillofacial Surgery, Department of Maxillofacial Surgery, Oslo University Hospital
Mats Døving, Dentist, Specialist in Maxillofacial Surgery and Senior Consultant, Department of Maxillofacial Surgery, Oslo University Hospital, and PhD Student, Faculty of Dentistry, University of Oslo
Pål Galteland, Dentist, Specialist in Maxillofacial Surgery, Senior Consultant and Head of Department, Department of Maxillofacial Surgery, Oslo University Hospital, and Associate Professor, Faculty of Dentistry, University of Oslo

Conflicts of Interest: None declared

Corresponding author: Ole Kristian Lobekk.
E-mail: olobekk@gmail.com

Accepted for publication 14.10.2026, The article is peer reviewed.

The article is cited as: Lobekk OK, Døving M, Galteland P. Delayed life-threatening bleeding following surgical tooth extraction. Nor Tannlegeforen Tid. 2026;136:

Keywords: Bleeding, liver disease, postoperative complication

Delayed life-threatening bleeding following surgical tooth extraction

Ole Kristian Lobekk, Mats Døving and Pål Galteland

This case report illustrates a rare instance in which the removal of a gauze packing following a tooth extraction resulted in severe and potentially life-threatening hemorrhage, despite an uncomplicated procedure six days earlier. The case highlights the challenges associated with infection-preventive dental treatment in patients with decompensated liver failure and emphasizes the inadequacy of conventional coagulation tests for predicting bleeding risk.

Patient and Background

A man in his late 50s presented to his general dental practitioner for the elimination of potential odontogenic foci of infection before planned liver transplantation. His medical history included liver cirrhosis with liver failure, chronic grade I hepatic encephalopathy, ascites, and esophageal varices. Other comorbidities included type 2 diabetes mellitus, hypothyroidism, and hyperlipidemia.

His regular medications were levothyroxine 50 µg once daily, carvedilol 3.125 mg once daily, spironolactone 25 mg once daily, furosemide 20 mg once daily, lactulose 20 ml twice daily, and rifaximin 550 mg twice daily.

Blood tests obtained approximately one month before dental treatment showed mild anemia, with a hemoglobin (Hb) concentration of 11.2 g/dL (reference range, 13.4–17.0 g/dL), thrombocytopenia, with a platelet count of 111×10^9/L (reference range, 145–390 $\times$ 10^9/L), and an elevated P-INR (Plasma International Normalized Ratio) of 1.6 (reference range, 0.9–1.2).

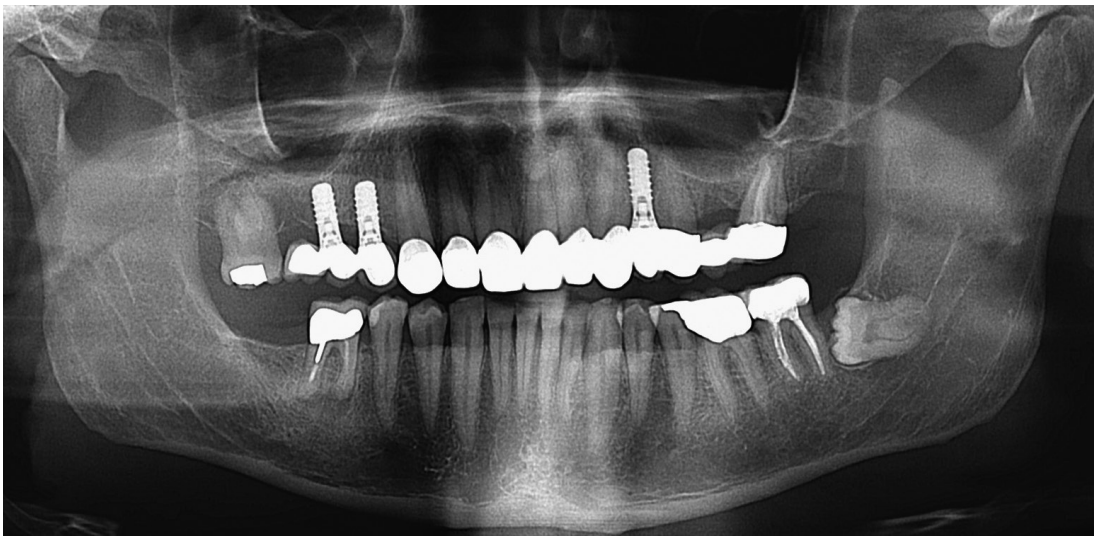

Figure 1 Panoramic radiograph. Tooth 38, horizontally impacted with surrounding pericoronal radiolucency. Tooth 46 with apical periodontitis.

Patient Management

Clinical and radiographic examination revealed secondary caries in tooth 35, which was excavated and restored with composite resin. Apical periodontitis was identified in tooth 46, which had an incomplete root canal filling and was restored with a post and crown. In addition, a 9–10 mm periodontal pocket was associated with a partially erupted, horizontally impacted mandibular third molar, tooth 38 (figure 1). Extraction of both tooth 46 and tooth 38 was planned.

Tooth 46 was extracted without complications. Three weeks later, tooth 38 was surgically removed, with no abnormal bleeding observed during the procedure. Gauze impregnated with Terramycin-polymyxin B was placed in the extraction socket, and the surgical site was sutured.

Six days later, removal of the gauze packing at the dental office immediately caused severe bleeding from the extraction socket. The dentist attempted local hemostatic measures, including compression, topical tranexamic acid, and packing of the socket with absorbable gelatin sponges, but bleeding control could not be achieved. The Emergency Medical Communication Centre (AMK) was alerted, and an ambulance crew and an anesthesiologist were dispatched to the dental clinic.

On arrival, the emergency team observed ongoing bleeding and severe hypotension, with a blood pressure of 75/37 mmHg. Intravenous access was established, and 20 µg of epinephrine and 1 g of tranexamic acid were administered intravenously. A plasma transfusion was also initiated. Direct compression of the extraction socket achieved partial control of the bleeding, and the patient was transported to hospital by ambulance under the supervision of the anesthesiologist.

On arrival at the emergency department, the patient was assessed by a surgical team, including a maxillofacial surgeon. His airway was patent, but bleeding from the extraction socket persisted despite continuous manual compression. His oxygen saturation was 100% while receiving oxygen at 12 L/min via a face mask. His respiratory rate was 12 breaths/min, blood pressure was 92/52 mmHg, and heart rate was 46 beats/min. He appeared pale but remained alert, with a Glasgow Coma Scale (GCS) score of 15. Arterial blood gas analysis revealed a decrease in Hb to 6.4 g/dL.

Transfusion of blood products was initiated immediately, comprising four units of packed red blood cells, four units of plasma, and one unit of platelet concentrate. The patient underwent nasotracheal intubation using a flexible bronchoscope under light sedation in the emergency department and was subsequently placed under general anesthesia. He was transferred directly to the operating theatre for surgical exploration of the extraction site.

A bleeding point was identified in the posterolateral aspect of the socket and controlled with diathermy. Minor diffuse oozing from the surrounding bone persisted and was controlled using local hemostatic agents, including a gelatin–thrombin matrix and oxidized regenerated cellulose. A mucoperiosteal flap was mobilized, for primary closure with resorbable sutures. The patient remained intubated overnight in the intensive care unit. He was extubated and transferred to the ward the following day.

The remainder of the hospital stay was uneventful, with no further bleeding episodes. Hb increased to 9.7 g/dL (reference range, 13.4–17.0 g/dL). Computed tomography angiography (CTA) re-

vealed no vascular malformation. Blood tests continued to show thrombocytopenia, with a platelet count of 88 × 10^9/L (reference range, 145–390 × 10^9/L), and an elevated P-INR of 1.8 (reference range, 0.9–1.2). The patient was discharged in stable condition two days after admission.

Discussion

Liver transplantation requires lifelong immunosuppressive therapy. Consequently, patients accepted for transplantation undergo dental assessment and treatment of potential foci of infection before transplantation {1]. Odontogenic infections may cause systemic complications both before and after transplantation. Potential sources include advanced caries, dental trauma, endodontic infections, and periodontal disease [2]. However, dental treatment in patients with liver failure is associated with an increased risk of intraoperative and postoperative bleeding, particularly during tooth extraction [3]. Managing dental disease in patients with decompensated liver cirrhosis therefore requires careful consideration of the competing risks of infection and hemorrhage.

Chronic liver disease affects both procoagulant and anticoagulant pathways, resulting in a rebalanced but fragile hemostatic system. Although this balance may be maintained under stable conditions, patients remain susceptible to both bleeding and thrombosis [4]. This altered hemostatic balance is not adequately reflected by the INR, which has limited value as a standalone predictor of bleeding risk in this population [4]. Thrombocytopenia is also common in chronic liver disease. However, elevated von Willebrand factor levels may partially compensate for reduced platelet counts, further limiting the usefulness of platelet count alone as a predictor of bleeding [4].

Despite these hemostatic abnormalities, tooth extraction can generally be performed safely in patients awaiting liver transplantation when appropriate local hemostatic measures are employed [5] [6][7]. Nevertheless, extraction of multiple teeth in a single session and surgical tooth removal may be associated with a greater risk of bleeding [8]. The risk may be further increased in patients with severe liver failure and substantial hepatic dysfunction, particularly when accompanied by a high predicted three-month mortality, as assessed using the Model for End-Stage Liver Disease (MELD) score. Acute-on-chronic decompensation, renal failure, and other systemic complications, including concurrent infection, may further increase this risk [2].

This case report describes severe, potentially life-threatening hemorrhage following removal of gauze packing from a surgical extraction socket, despite an uneventful extraction six days earlier. Subsequent investigation identified no vascular malformation to explain the bleeding, and the precise cause of the hemorrhage could not be established. The patient's underlying liver disease may have contributed to impaired hemostatic reserve, while mechanical disruption during removal of the packing may have triggered bleeding from a local vessel within the socket.

Although preoperative laboratory investigations revealed mild anemia, thrombocytopenia, and an elevated INR, these abnormalities have limited predictive value when considered individually. This case highlights the difficulty of predicting bleeding complications from conventional coagulation parameters alone.

Conclusion

For patients with advanced or decompensated liver disease, dental treatment should be planned on an individualized basis in collaboration with the liver transplantation team and an oral and maxillofacial surgeon. Treatment in a hospital setting should be considered when the anticipated procedural complexity and the patient's overall clinical condition indicate an increased risk of serious complications.

The patient has provided written informed consent for the publication of this case report and accompanying images.

REFERENCES

1. Oslo universitetssykehus. 2026. Utredning og vurdering for levertransplantasjon. eHåndbok OUS. [Retrieved 18.08.2026). Available from: https://ehandboken.ous-hf.no/document/134946
2. Dove L, Chadha RM, Lai JC, DiMartini A, Liapakis A, Parikh ND et al. AASLD AST Practice Guideline on adult liver transplantation: Candidate evaluation. Hepatology. 2026;83(6):1609–1645. https://doi.org/10.1097/HEP.0000000000001644
3. Giltvedt KM, Bjørnland T, Olsen-Bergem H. Hvordan håndtere pasienter med økt blødningsrisiko. Nor Tannlegeforen Tid. 2020;131:318–24. https://doi.org/10.56373/2020-4-4
4. Tripodi A, Mannucci PM. The coagulopathy of chronic liver disease. N Engl J Med. 2011;365(2):147–56. https://doi.org/10.1056/NEJMra1011170
5. de Oliveira Rech B, Rocha Tenório J, Bertoldi Franco J, Medina JB, Gallottini M, Pérez-Sayáns M, et al. Risk of bleeding during oral surgery in patients with liver cirrhosis: A systematic review. J Am Dent Assoc. 2021;152(1):46–54.e2. https://doi.org/10.1016/j.adaj.2020.09.018
6. Medina JB, Andrade NS, de Paula Eduardo F, Bezinelli L, Franco JB, Gallottini M, et al. Bleeding during and after dental extractions in patients with liver cirrhosis. Int J Oral Maxillofac Surg. 2018;47(12):1543–1549. https://doi.org/10.1016/j.ijom.2018.04.007
7. Perdigão JP, de Almeida PC, Rocha TD, Mota MR, Soares EC, Alves AP, et al. Postoperative bleeding after dental extraction in liver pretransplant patients. J Oral Maxillofac Surg. 2012;70(3):e177–84. https://doi.org/10.1016/j.joms.2011.10.033
8. Ward BB, Weideman EM. Long-term postoperative bleeding after dentoalveolar surgery in the pre-transplant liver failure patient. J Oral Maxillofac Surg. 2006 Oct;64(10):1469-74. https://doi.org/10.1016/j.joms.2006.05.044